

Hepatocellular Carcinoma with Tumor Thrombus in the Inferior Vena Cava and Right Atrium

Arsh Gupta, Neera Sinha*, Stephen Mularz, Michael Bernstein

ABSTRACT

We present a rare case of hepatocellular carcinoma with associated tumor thrombus that extends into the inferior vena cava and right atrium. Our patient presented with lower extremity edema and an elevated D-dimer. CT pulmonary angiography showed no signs of pulmonary embolism however it showed large filling defects involving the inferior vena cava, right atrium, right ventricle and superior vena cava suggestive of an extensive thrombus. On subsequent imaging studies it was identified as a tumor thrombus as opposed to a blood thrombus. A tumor thrombus is a rare complication more commonly associated with renal cell carcinoma and carries a poor prognosis. Surgical thrombectomy is considered the first line of treatment at this time, however, due to the low number of known cases to have IVC and RA involvement, there is little consensus on management. Often patients are referred for microwave ablation. Anti-coagulation is not the treatment of choice for a tumor thrombus however we speculate there may be a role for anti-coagulation.

Key words: Tumor, Thrombus, Hepatocellular, Carcinoma, Right, Atrium.

INTRODUCTION

Macrovascular invasion is a well-recognized finding of advanced hepatocellular carcinoma and portal vein tumor thrombus is the most frequently associated type. Hepatic vein thrombus has been identified in 2% of HCC and only 0.67-3% of these patients develop tumor thrombus in the inferior vena cava (IVC) with extension into the right atrium (RA).^[1] Here we present a case of a 62-year-old male who had an incidental finding of tumor thrombus as the initial presentation of presumed HCC.

Case Presentation

A 62-year-old male with a history of hepatitis B on tenofovir presented with dry mouth, sore throat and generalized weakness. His physical examination was remarkable for hepatomegaly and bilateral lower extremity edema. His ALP, AST and ALT levels were 190U/L, 189U/L and 130U/L respectively and d-dimer level was 747ng/mL, otherwise all other initial labs were unremarkable. A venous doppler study of the lower extremities was negative for deep venous thrombosis. CT pulmonary angiography (CTA) had no evidence of pulmonary embolism however did show large filling defects involving the IVC, RA, right ventricle and superior vena cava, suggestive of an extensive thrombus that appeared to be contiguous with an intrahepatic mass [Figure 1].

Transthoracic echocardiogram revealed a large mobile mass in the RA without signs of right heart strain and a distinct filling defect in the IVC [Figure

2]. The patient was started on unfractionated heparin drip for anticoagulation of the thrombus. His presenting complaints of dry mouth and sore throat were concluded to be secondary to tenofovir. Further laboratory data revealed an Alpha Fetoprotein (AFP) level of 2200ng/mL. All other tumor marker levels were within the normal range. In the setting of his underlying hepatitis B, elevated AFP and intrahepatic mass on imaging, it was suspected that the patient likely had HCC.

On day 1 of hospitalization, cardiovascular surgery was asked to evaluate the case and the patient was offered surgical extraction of the thrombus, for which he agreed. He was transferred to a tertiary center which provided cardiovascular surgical services. Following transfer, anticoagulation was continued and a repeat CTA was obtained which revealed similar findings to the initial study. MRI of the abdomen was obtained which confirmed an intrahepatic mass with a 6cm diameter. Positron emission tomography (PET) scan revealed increased uptake by the hepatic mass, IVC and RA thrombus; the patient was diagnosed with tumor thrombus and anticoagulation therapy was discontinued. He was offered simultaneous surgical extraction of both the tumor thrombus and the intrahepatic mass but the patient refused any surgical procedure. He was offered percutaneous microwave ablation (MWA) of the tumor thrombus, which he also refused. The patient opted for supportive measures only and was

Arsh Gupta, Neera Sinha*,
Stephen Mularz, Michael
Bernstein

Department of Internal Medicine,
Coney Island Hospital, 2601 Ocean
Pkwy, Brooklyn, NY 11235, USA

Correspondence

Dr. Neera Sinha, MD

Coney Island Hospital, Department of
Internal Medicine, 2601 Ocean Pkwy,
Brooklyn, NY 11235, USA.

Phone: +1-732-600-2432

Email: nsinha216@gmail.com

History

- Submission Date: 05-09-2018;
- Review completed: 18-10-2018;
- Accepted Date: 05-11-2018.

DOI : 10.5530/ogh.2018.7.2.1

Article Available online

<http://www.oghreports.org/v7/i2>

Copyright

© 2018 Phcog.Net. This is an open-access article distributed under the terms of the Creative Commons Attribution 4.0 International license.

Cite this article: Gupta A, Sinha N, Mularz S, Bernstein M. Hepatocellular Carcinoma with Tumor Thrombus in the Inferior Vena Cava and Right Atrium. OGH Reports. 2018;7(2):95-7.

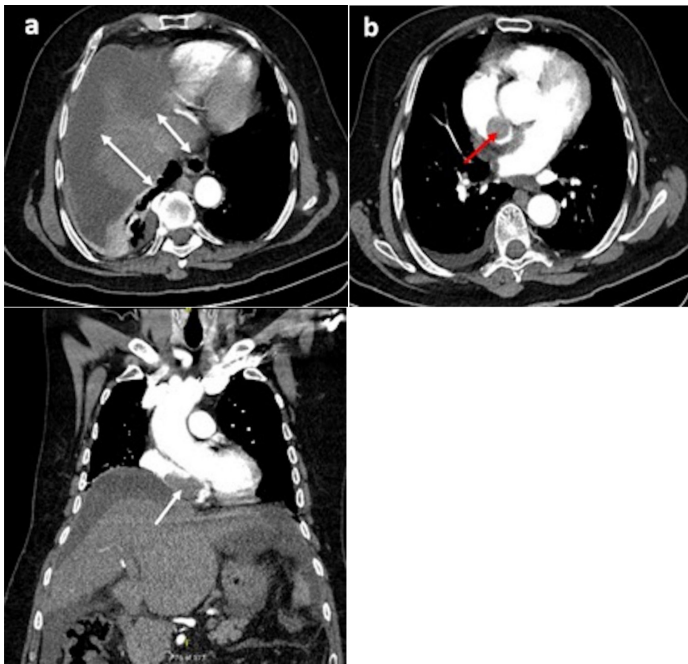


Figure 1: CTA demonstrating findings: **a** Intra-hepatic mass (white arrow) with filling defects in a dilated IVC (white arrow). **b** Filling defects noted in the RA (red arrow). **c.** coronal view of filling defect in the IVC (white arrow)

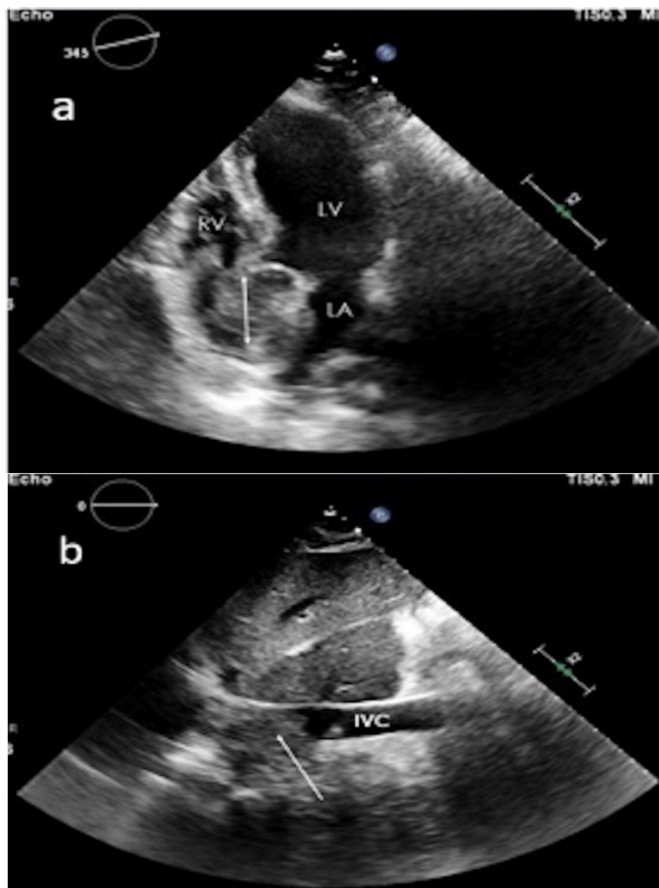


Figure 2: Transthoracic Echocardiogram demonstrating findings: **a** Thrombus present in the RA (white arrow). **b** Filling defect in the IVC (white arrow)

discharged to return to his home country where he elected for hospice care.

DISCUSSION

The pathophysiology behind the development of a tumor thrombus is not well understood, but it is suggested that it may be due to the activation of hemostasis that occurs in cases of advanced HCC.^[2] Aggressive tumor pathology; tumor diameter >5cm or AFP >1000ng/mL, as is seen in this case, have been most commonly associated with tumor thrombus development.^[3,4] Extension of the tumor thrombus can correlate with prognosis and IVC or RA involvement is associated with extremely poor prognosis, with a median survival of 2 months if no intervention is made.^[5-6]

Patients with tumor thrombus in the IVC and RA can present with similar symptoms and signs as patients with a 'bland' (blood) thrombus. Furthermore, their appearance is almost indistinguishable on initial imaging which makes differentiating the two types of thrombi difficult. There is now a consensus that use of PET scan, showing increased uptake by the tumor thrombus when compared to a blood thrombus, can be used to distinguish the two entities.^[7] In our case, the patient's initial chest CTA led us to believe there was a blood thrombus extending into the IVC and right atrium and the patient was started on therapeutic anticoagulation.

Surgical resection remains the mainstay of treatment for tumor thrombus and complete resection can have 5-year survival rates of up to 50%.^[1] Anticoagulation is not the treatment of choice for a tumor thrombus, emphasizing the importance of distinguishing it from a bland thrombus, though this is based on a small number of cases without significant literature.^[8] Due to their cirrhosis and underlying malignancy these patients are considered hypercoagulable and in the setting of a tumor thrombus with subsequent disruption of circulation, they are likely at increased risk of developing blood thrombi. It can therefore be speculated that anticoagulation could prolong survival in these patients by preventing formation of superimposed bland thrombi.

Although the patient in our case opted for no intervention, there are multiple cases of tumor thrombi with attempted treatment. Surgical therapy is presumed to be the most effective. However, surgical intervention requires cardiopulmonary bypass and at the time of diagnosis, many patients are at an advanced age with a higher risk of operative failure and complications.^[9] More commonly, MWA is being offered to these patients. One study describes a case of advanced HCC with tumor thrombus occupying the IVC and RA that was successfully ablated, increasing the survival of the patient to 16 months.^[9] However, the scarce number of known cases with a successful outcome following treatment makes management of these patients extremely difficult and many patients opt for supportive care only.

In conclusion, surgical thrombectomy is a viable treatment for tumor thrombus however there is no consensus on how to improve the post-surgical prognosis. There is also no standard of care for non-surgical candidates, although MWA may be a valuable alternative therapy to surgery. Furthermore, many of these patients may have a mixed case of tumor thrombus and blood thrombus and there may be a role for anticoagulation in these patients, which is a potential topic for future investigation. The incidence of HCC with a tumor thrombus extending into the IVC and RA is rare and this case serves to increase awareness of diagnosis and treatment options.

REFERENCES

- Huang J, Pan Z-Y, Li L, Jiang B-G, Gu FM, Wang Z-G, et al. Hepatocellular carcinoma with inferior vena cava and right atrial tumor thrombi and massive pulmonary artery embolism. A case report. *Molecular and Clinical Oncology*.

- 2017;6(1):111-4.
2. Connolly GC, Chen R, Hyrien O, Mantry P, Bozorgzadeh A, Abt P, *et al.* Incidence, risk factors and consequences of portal vein and systemic thrombosis in hepatocellular carcinoma. *Thromb Res.* 2008;122(3):299-306.
 3. Sakata J, Shirai Y, Wakai T, Kaneko K, Nagahashi M, Hatakeyama K. Preoperative predictors of vascular invasion in hepatocellular carcinoma. *Eur J Surg Oncol.* 2008;34(8):900-5.
 4. Bruix J, Sherman M. American Association for the Study of Liver Diseases. Management of hepatocellular carcinoma: An update. *Hepatology.* 2011;53(3):1020-2.
 5. Lin HH, Hsieh CB, Chu HC, Chang WK, Chao YC, Hsieh T. Acute pulmonary embolism as the first manifestation of hepatocellular carcinoma complicated with tumor thrombi in the inferior vena cava: Surgery or not?. *Dig Dis Sci.* 2007;52(6):1554-7.
 6. Saynak M, Ozen A, Kocak Z, Cosar-Alas R, Uzal C. Sudden death: a case report of hepatocellular carcinoma with tumor thrombus extending into the right atrium. *J Buon.* 2007;12(4):556.
 7. Sharma P, Kumar R, Jeph S, Karunanithi S, Naswa N, Gupta A, Malhotra A. 18F-FDG PET-CT in the diagnosis of tumor thrombus: can it be differentiated from benign thrombus?. *Nuclear Medicine Communications.* 2011;32(9):782-8.
 8. Luo X, Zhang B, Dong S, Zhang B, Chen X. Hepatocellular carcinoma with Tumor Thrombus occupying the Right Atrium and Portal Vein. *Medicine; Clinical Case Report.* 2015;94(4).
 9. Li W, Wang Y, Gao W, Zheng J. HCC with tumor thrombus entering the right atrium and inferior vena cava treated by percutaneous ablation. *BMC Surgery.* 2017;17(1): 21.

Cite this article: Gupta A, Sinha N, Mularz S, Bernstein M. Hepatocellular Carcinoma with Tumor Thrombus in the Inferior Vena Cava and Right Atrium. *OGH Reports.* 2018;7(2):95-7.