

Omental infarction presenting as abdominal pain typical for cholecystitis

Abstract

To describe a patient who presented to a family medicine clinic with symptoms typical for cholecystitis, but eventually was diagnosed with omental infarction. A 37-year-old Caucasian man reported with right upper quadrant pain suspicious for cholecystitis. In light of negative abdominal ultrasound, computed tomography scan was performed, and omental infarction was identified. The patient was treated conservatively with a good outcome. Omental infarction is rarely described in medical literature, and it is often missed or misdiagnosed. There are increasing numbers of reports that describe omental infarction being diagnosed as various types of acute abdomen. With increased utilization of advanced imaging, omental infarction is being found to be responsible for presentations of the acute abdomen that were misdiagnosed. Proper diagnosis prevents invasive mismanagement and an unnecessarily prolonged hospital stay.

Key words: Acute abdomen in family practice, omental infarction in family practice, Omental Infarction resembling cholecystitis

INTRODUCTION

The typical patient with omental infarct is a middle-aged man with right upper or lower quadrant abdominal pain.^[1] Due to the rare incidence and nonspecific presentation, this condition is rarely considered. The manifestation of right-sided pain may lead to clinical misdiagnosis as appendicitis or cholecystitis; thus, imaging is required to achieve an accurate diagnosis and to avoid unnecessary laparotomy and antibiotic therapy.^[1-3] The condition may also mimic peptic ulcer disease, pancreatitis, and diverticulitis.^[2] Even though, the condition presents as acute abdomen, omental infarction management is usually conservative. Until the beginning of this century, omental infarcts were seldom diagnosed and most of these patients ended up getting antibiotic treatments and/or laparoscopic surgeries.^[3] With the recent advancements of imaging modalities, omental infarcts are being diagnosed with increased accuracy, thus avoiding unnecessary medical as well as surgical treatments. We describe a case of omental infarct that was successfully diagnosed by a computed tomography (CT) scan and then managed conservatively with a very good response.

CASE REPORT

A 37-year-old Caucasian man with a remote history of drug abuse resulting in heart cardiomyopathy and present history of alcoholism reported to the Family Medical Center with a 3-day history of right upper quadrant pain. The patient described the pain as an intermittent aching. The pain onset was gradual and associated with some nausea but no vomiting. No known dietary errors, sick contacts, fever/chills, or diarrhea/constipation were reported. The pain had a questionable association with food ingestion (initially the patient denied but later stated “maybe”). He reported to an outside hospital emergency department at the time of onset of his pain. Per his reports all the blood work was negative and the right upper quadrant ultrasound, which was of poor quality due to gall bladder constriction, was negative as well. The day before he presented to the clinic, the patient reported to another emergency department for persistent symptoms in the form of episodic abdominal pain. Once again his labs were negative and this time the right upper quadrant ultrasound was good quality and negative for cholelithiasis or other gall bladder abnormalities.

At the time of presentation to our clinic, the patient did not appear to be in distress but on his abdominal exam he was severely tender in the right upper quadrant with positive Murphy sign. The

**Pawel Dutkiewicz,
Shashank Kraleti,
Diane Jarrett**

Department of Family and Preventive Medicine, College of Medicine, University of Arkansas for Medical Sciences, Little Rock, USA

Address for the Correspondence:

Dr. Pawel Dutkiewicz,
Department of Family and Preventive Medicine, University of Arkansas for Medical Sciences, College of Medicine, 521 Jack Stephens Drive, Little Rock, AR 72205, USA.
E-mail: PMDutkiewicz@uams.edu

Access this article online

Website: www.oghr.org

DOI: 10.4103/2348-3113.159100

Quick response code:



remainder of abdominal exam was unremarkable. Vital signs on presentation showed a blood pressure of 130/76 mmHg and heart rate of 80 beats/min. Temperature was 98°F and respiratory rate was 20 breaths/min. Lab values including complete blood count, renal chemistry, lipase and amylase were normal.

C-reactive protein was 62.70 and erythrocyte sedimentation rate was 21. Due to his clinical presentation and multiple visits without yielding diagnosis, the patient was admitted to the hospital for observation. At the time of admission, CT scan of the abdomen that was done showed a solitary, heterogeneous omental mass with surrounding inflammatory stranding in the right lower quadrant anterior to the ascending colon, consistent with omental infarct [Figures 1 and 2]. Otherwise, no other abnormality was noted in the abdomen and pelvis. The patient was managed conservatively and discharged after 24 h of observation. On the follow-up visit in the clinic at 7 days after discharge, the patient was free of all symptoms.

DISCUSSION

The omentum is a fat-laden peritoneal remnant of embryological development and is anatomically divided into the greater and lesser omentum. Omental infarction is a rare cause of acute abdomen resulting from vascular compromise of the greater omentum. Its incidence is <4 cases per 1000 cases of appendicitis.^[3,4]

Adults represent close to 85% of all reported cases of omental infarction with children representing 15%.^[5] The most common age at presentation is between 40 and 50 years with studies showing predominance in males reaching up to 2:1 ratio.^[6] The incidence is low ranging from 8 cases over 35 years to 9 cases over 8 years depending on the study with a total of about 400 cases reported since the 1950s.^[5,7] The variety of ways omental infarct can present is oftentimes confusing to the diagnosing physician and may lead to suboptimal treatment.

Omental infarction can be of primary or idiopathic origin or secondary to conditions like hypercoagulability, vasculitis, or

polycythemia. Omental torsion resulting from cysts, tumors, and adhesions is one of the common secondary causes. Omental infarction is usually located on the right side, which is believed to be a consequence of omental mobility being greater on the right side when compared to left.^[8] Risk factors for omental torsion include visceral obesity, abdominal injury, sudden body movements, heavy food intake and laxative use.^[1,6] Regardless of the initial inciting factor, histologically the process usually starts with edema and advances through venous stasis ultimately leading to hemorrhagic necrosis.^[6,9,10]

Diagnosis is oftentimes challenging as there are no symptoms pathognomonic for omental infarction. The reported percentage of correct preoperative diagnosis is just 0.6–4.8%.^[4] Correct diagnosis can be made with CT imaging showing a “whirl” sign or streaky infiltration [Figure 2].^[3] Still in some cases even with use of CT the diagnosis is difficult to establish as abovementioned radiographic signs may be present in cases of epiploic appendagitis, mesenteric lipodystrophy or omental tumors such as lipoma, liposarcoma, or teratoma. Given these factors correct diagnosis may necessitate diagnostic laparoscopy.^[4] Whether omental infarction is primary or secondary to torsion can be distinguished only during surgery.^[1] Once the diagnosis is made, conservative management with adequate analgesia, hydration and reintroduction of oral intake as tolerated should be attempted. Surgical intervention is rarely needed but is appropriate in cases of persisting peritoneal signs or inability to tolerate oral alimentation.

CONCLUSION

Omental infarction is frequently misdiagnosed as appendicitis or cholecystitis leading to unnecessary treatment and hospitalizations. In our opinion, all unclear objective abdominal findings suggestive of peritoneal irritation should be investigated with advanced imaging techniques such as CT with contrast. Once the diagnosis is established conservative management with adequate analgesia is preferred initially with close monitoring of symptoms over 24–48 h. Physicians should

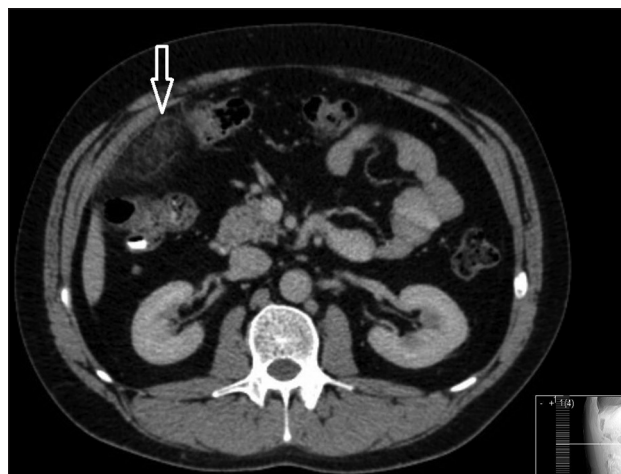


Figure 1: Omental infarction

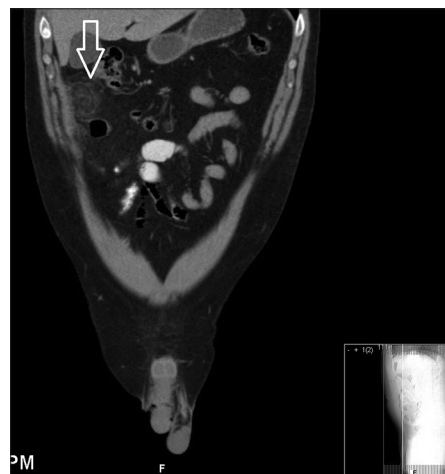


Figure 2: Classic “whirl” sign present

have a low threshold for operative management in case of lack of improvement or worsening symptoms as cases of intraabdominal abscess originating from omental infarct were reported.^[1,8,12] From our experience if no complications occur, the symptoms should gradually improve and resolve within 7–10 days. Since most of the literature describing omental infarction is being published in radiology, surgery or emergency medicine journals, we believe it is important to make this topic more available to family physicians.

REFERENCES

1. Singh AK, Gervais DA, Lee P, Westra S, Hahn PF, Novelline RA, *et al.* Omental infarct: CT imaging features. *Abdom Imaging* 2006;31:549-54.
2. Barai KP, Knight BC. Diagnosis and management of idiopathic omental infarction: A case report. *Int J Surg Case Rep* 2011;2:138-40.
3. Itenberg E, Mariadason J, Khersonsky J, Wallack M. Modern management of omental torsion and omental infarction: A surgeon's perspective. *J Surg Educ* 2010;67:44-7.
4. Scabini S, Rimini E, Massobrio A, Romairone E, Linari C, Scordamaglia R, *et al.* Primary omental torsion: A case report. *World J Gastrointest Surg* 2011;3:153-5.
5. Karak PK, Millmond SH, Neumann D, Yamase HT, Ramsby G. Omental infarction: Report of three cases and review of the literature. *Abdom Imaging* 1998;23:96-8.
6. Park TU, Oh JH, Chang IT, Lee SJ, Kim SE, Kim CW, *et al.* Omental infarction: Case series and review of the literature. *J Emerg Med* 2012;42:149-54.
7. Paroz A, Halkic N, Pezzetta E, Martinet O. Idiopathic segmental infarction of the greater omentum: A rare cause of acute abdomen. *J Gastrointest Surg* 2003;7:805-8.
8. Abdulaziz A, El Zalabany T, Al Sayed AR, Al Ansari A. Idiopathic omental infarction, diagnosed and managed laparoscopically: A case report. *Case Rep Surg* 2013;2013:193546.
9. Cianci R, Filippone A, Basilico R, Storto ML. Idiopathic segmental infarction of the greater omentum diagnosed by unenhanced multidetector-row CT and treated successfully by laparoscopy. *Emerg Radiol* 2008;15:51-6.
10. Leitner MJ, Jordan CG, Spinner MH, Reese EC. Torsion, infarction and hemorrhage of the omentum as a cause of acute abdominal distress. *Ann Surg* 1952;135:103-10.
11. Goti F, Hollmann R, Stieger R, Lange J. Idiopathic segmental infarction of the greater omentum successfully treated by laparoscopy: Report of case. *Surg Today* 2000;30:451-3.
12. Balthazar EJ, Lefkowitz RA. Left-sided omental infarction with associated omental abscess: CT diagnosis. *J Comput Assist Tomogr* 1993;17:379-81.

How to cite this article: Dutkiewicz P, Kraleti S, Jarrett D. Omental infarction presenting as abdominal pain typical for cholecystitis. *Onc Gas Hep Rep* 2016;5:40-2.

Source of Support: Nil, **Conflict of Interest:** None declared.