

Image findings of a rare case of gestational breast cancer diagnosed in a lactating woman with Fluorine-18 fluorodeoxyglucose-positron emission tomography/computed tomography

Abstract

Gestational or pregnancy-associated breast cancer is defined as breast cancer that is diagnosed during pregnancy, in the first post-partum year or any time during lactation. We report a rare imaging finding of breast cancer seen on fluorodeoxyglucose-positron emission tomography/computed tomography (FDG PET/CT) study in a 32-year-old lactating woman. The FDG PET/CT study demonstrated uptake in the soft tissue lesion noted in the right breast corresponding to the primary lesion and multiple nodes in the bilateral axilla, right supraclavicular and mediastinum. In addition, there was FDG tracer uptake in both the breast parenchyma related to breast feeding. This case illustrates the first case of breast cancer in a lactating woman described in FDG PET/CT.

Key words: Fluorodeoxyglucose positron emission tomography/computed tomography, gestational breast cancer, lactating breast uptake, staging

**Koramadai Karuppusamy
Kamaleshwaran,
Sudhakar Natarajan¹,
Firoz Rajan¹,
Vyshak Mohanan,
Ajit Sugunan Shinto**

Departments of Nuclear Medicine and PET/CT and ¹Oncology, Comprehensive Cancer Care Centre, Kovai Medical Centre and Hospital Limited, Coimbatore, Tamil Nadu, India

Address for the Correspondence:

Dr. Koramadai Karuppusamy
Kamaleshwaran,
Department of Nuclear Medicine,
PET/CT and Radionuclide
Therapy, Comprehensive Cancer
Care Centre, Kovai Medical
Centre and Hospital Limited,
Coimbatore - 641 014,
Tamil Nadu, India.
E-mail:
dr.kamaleshwar@gmail.com

Access this article online

Website: www.oghr.org

DOI: 10.4103/2348-3113.134214

Quick response code:



INTRODUCTION

The incidence of pregnancy-associated breast cancer (for the pre-natal to post-partum periods) is approximately 15-35 per 100,000 deliveries, with fewer breast cancer cases diagnosed during pregnancy than during the first post-partum year.^[1] Women with a genetic predisposition to breast cancer may be overrepresented among pregnant women with cancer, although the available evidence is limited.^[2] There are no previous reports of F-18 fluorodeoxyglucose-positron emission tomography/computed tomography (FDG PET/CT) in a lactating woman with breast cancer.

CASE REPORT

A 32-year-old female patient who had delivered a child 2 months back and was breast feeding presented with a lump in the right breast. She underwent an excision biopsy of the breast lump, which showed invasive ductal carcinoma. As a part of the evaluation, she was subjected to a PET/CT scan, which was performed on a hybrid scanner after injection of approximately 10 mCi of F-18 FDG. Maximum intensity projection image [Figure 1, right down] showed diffusely increased FDG uptake in both the breasts due to lactation, and intense FDG uptake was noted in the right breast mass lesion. CT, fused PET/CT and PET transaxial image [Figure 1, right and left] at the level of the breast showed increased FDG uptake in the bilateral breast parenchyma and multiple nodes. As the PET/CT scan confirmed metastatic involvement of multiple nodes, the patient underwent chemotherapy.

DISCUSSION

Breast cancer is one of the most common cancers in non-pregnant and pregnant women.^[1] Up to 20% of breast cancers in women under the age of 30 years are pregnancy-associated, but fewer than 5% of breast cancers diagnosed in women under the age of 50 years are detected during pregnancy or in the post-partum period.^[2] FDG PET/CT in breast cancer imaging has an adjunctive role in the detection of locoregional recurrence or distant metastases in locally advanced breast cancer

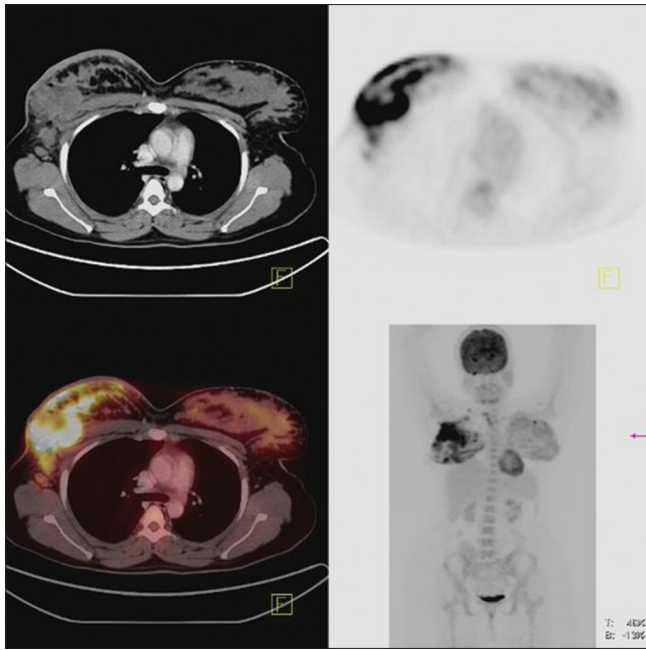


Figure 1: Whole body fluorodeoxyglucose-positron emission tomography/computed tomography (PET/CT) maximum intensity projection image, Axial CT, PET, fused PET/CT showed an intense uptake in the soft tissue lesion in the right breast. Also, bilateral breast parenchyma uptake due to lactation was noted

when results of other standard imaging techniques are equivocal or suspicious.^[3] Increased FDG uptake in lactation is thought to be the result of uptake of plasma glucose for milk production and increased activity of the ductal muscles.^[4-6] Hicks *et al.*^[7] described that most of the patients who were breast-feeding an infant before PET scanning had diffuse and symmetric uptake in the breasts. Asymmetric breast uptake in lactating women and in a patient with hydatid cyst has been described.^[8,9] To the best of our knowledge, this is the first case report of breast cancer with

lactating breast uptake detected on FDG PET scan. FDG uptake pattern has been useful in predicting the benign or malignant nature of nodes. In our case, as the PET study revealed multiple nodal metastasis, the patient was subjected to chemotherapy. Our case thus illustrates that FDG PET/CT is an important imaging modality for the detection and accurate staging and restaging of breast cancer and to decide upon appropriate treatment even in a lactating woman.

REFERENCES

1. Antonelli NM, Dotters DJ, Katz VL, Kuller JA. Cancer in pregnancy: A review of the literature. Part I. *Obstet Gynecol Surv* 1996;51:125-34.
2. Wallack MK, Wolf JA Jr, Bedwinek J, Denes AE, Glasgow G, Kumar B, *et al.* Gestational carcinoma of the female breast. *Curr Probl Cancer* 1983;7:1-58.
3. Crowe JP Jr, Adler LP, Shenk RR, Sunshine J. Positron emission tomography and breast masses: Comparison with clinical, mammographic, and pathological findings. *Ann Surg Oncol* 1994;1:132-40.
4. Yasuda S, Fujii H, Takahashi W, Takagi S, Ide M, Shohtsu A. Lactating breast exhibiting high F-18 FDG uptake. *Clin Nucl Med* 1998;23:767-8.
5. Bakheet SM, Powe J, Kandil A, Ezzat A, Rostom A, Amartey J. F-18 FDG uptake in breast infection and inflammation. *Clin Nucl Med* 2000;25:100-3.
6. Dankerl A, Schirmeister H, Buck A, Reske SN. Elevated FDG uptake in the lactating human breast. *Clin Nucl Med* 2001;26:577-8.
7. Hicks RJ, Binns D, Stabin MG. Pattern of uptake and excretion of (18) F-FDG in the lactating breast. *J Nucl Med* 2001;42:1238-42.
8. Shor M, Dave N, Reddy M, Ali A. Asymmetric FDG uptake in a lactating breast. *Clin Nucl Med* 2002;27:536.
9. Abhyankar A, Joshi J, Basu S. FDG uptake in unilateral breast related to breastfeeding practice in a patient of pulmonary hydatid cyst. *Clin Nucl Med* 2012;37:676-8.

How to cite this article: Kamaleshwaran KK, Natarajan S, Rajan F, Mohanan V, Shinto AS. Image findings of a rare case of gestational breast cancer diagnosed in a lactating woman with Fluorine-18 fluorodeoxyglucose-positron emission tomography/computed tomography. *Onc Gas Hep Rep* 2014;3:34-5.

Source of Support: Nil, **Conflict of Interest:** None declared.

Announcement

iPhone App



Download
**iPhone, iPad
application**

FREE

A free application to browse and search the journal's content is now available for iPhone/iPad. The application provides "Table of Contents" of the latest issues, which are stored on the device for future offline browsing. Internet connection is required to access the back issues and search facility. The application is Compatible with iPhone, iPod touch, and iPad and Requires iOS 3.1 or later. The application can be downloaded from <http://itunes.apple.com/us/app/medknow-journals/id458064375?ls=1&mt=8>. For suggestions and comments do write back to us.